

Foot & Ankle International

<http://fai.sagepub.com/>

3D-Imaging (ARCADIS) Based Computer Assisted Surgery (CAS) Guided Drilling for Screw Placement in Subtalar Fusion

Martinus Richter, Stefan Zech and Raymund Bay
Foot Ankle Int 2009 30: 163
DOI: 10.3113/FAI-2009-0163

The online version of this article can be found at:
<http://fai.sagepub.com/content/30/2/163>

Published by:



<http://www.sagepublications.com>

On behalf of:



[American Orthopaedic Foot & Ankle Society](http://www.aofas.org)

Additional services and information for *Foot & Ankle International* can be found at:

Email Alerts: <http://fai.sagepub.com/cgi/alerts>

Subscriptions: <http://fai.sagepub.com/subscriptions>

Reprints: <http://www.sagepub.com/journalsReprints.nav>

Permissions: <http://www.sagepub.com/journalsPermissions.nav>

>> [Version of Record](#) - Feb 1, 2009

[What is This?](#)

3D-Imaging (ARCADIS) Based Computer Assisted Surgery (CAS) Guided Drilling for Screw Placement in Subtalar Fusion

Martinus Richter, MD, PhD; Stefan Zech, MD; Raymund Bay, MD
Coburg, Germany

INTRODUCTION

Subtalar arthrodesis with deformity correction is one option after a malunited calcaneus fracture that can provide good functional outcome.^{2,4,9-11} Screw fixation with two parallel retrograde screws provides good stability and allows compression.^{2,4,9-12} The correct placement of the screws for fixation in a subtalar correction arthrodesis can be difficult.³ We have earlier introduced a 2D imaging-based Computer Assisted Surgery (CAS) guided correction of the calcaneus in relation to the talus.^{5,6} Due to difficulties in visualizing the bones and starting and endpoints for drilling, and consequent potential inaccuracies, we have switched to a 3D imaging-based method for the drilling.^{5,6}

We assumed that a 3D imaging-based CAS guided drilling for this purpose is feasible and accurate since the 3D method was more accurate than the conventional 2D imaging for retrograde drilling of osteochondritis dissecans of the talus.^{1,8} Another advantage of this method is that the 3D-imaging before insertion of the definitive implants allows better assessment of the earlier correction than 2D imaging^{5,6} thus improving correction before definitive fixation.⁵⁻⁷ This new method of 3D imaging (ARCADIS)-based CAS guided drilling for screw placement for subtalar fusion is introduced (model ARCADIS, Siemens Medical Inc., Munich, Germany, and model Navivision, Brainlab Inc., Heimstetten, Germany).

No benefits in any form have been received or will be received from a commercial party related directly or indirectly to the subject of this article.

Corresponding Author:

Martinus Richter, MD, PhD
Klinik für Unfallchirurgie, Orthopädie und Fusschirurgie
Klinikum Coburg
Ketschendorfer Str. 33
96450 Coburg
Germany
E-mail: info@foot-trauma.org
For information on pricings and availability of reprints, call 410-494-4994, x226.

OPERATIVE TECHNIQUE

The patient is placed in the prone position. A posterolateral approach is used. The corrected position of the calcaneus in relation of the talus is performed with 2D imaging-based CAD guidance as previously described.^{5,6} For this navigation, one Dynamic Reference Base (DRB) is placed into the talar neck through an additional anterolateral stab incision, and one DRB is placed into the posterior process through the posterolateral incision. During the CAS guided correction, bone grafting with two autologous tricortical bone blocks and cancellous bone from the posterior pelvic rim and fixation between the calcaneus and talus with two 2.0-mm titanium Kirschner wires is performed. Titanium was used to minimize the artifact encountered with later 3D imaging. Then the DRB from the calcaneus is removed to minimize artifact. The 2D navigation cage that was used for the CAS guided correction is removed and the situs is draped with a sterile plastic bag. The 3D-imaging dataset was obtained by an ARCADIS scan (Figure 1). With the 3D reformations, accurate correction of the calcaneus in relation to the talus is checked (Fig. 1B). Two parallel drill paths are planned with a starting point at the posterior calcaneal process (Figure 2). Then the drillings are performed with a CAS guided 5-mm drill (Figure 3). Two 7.3-mm cancellous screws with short threads and standard washers (Synthes, Umkirch, Germany) are inserted. The Kirschner wires and DRB are removed. A 3D ARCADIS imaging then analyzes the correction and screw position (Figure 4). The process of CAS guided drilling and insertion of screws takes 10 minutes. The entire surgery in this example took 204 minutes. The image contamination is comparable to 104 pulsed digital fluoroscopic images or 42 seconds of pulsed fluoroscopic imaging. Half of this radiation contamination occurs with the 2D screw navigation also, because one ARCADIS 3D scan is usually performed to assess bone and implant position after 2D navigation.

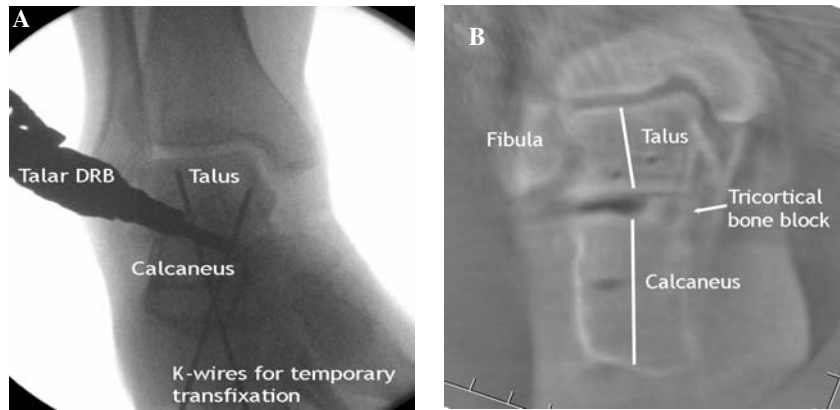


Fig. 1: Intraoperative image acquisition with ARCADIS. **A**, 2D-image without sufficient visibility of the drilling entry- or endpoint. **B**, Coronal reformation of the 3D-dataset from the ARCADIS scan with good visibility of the entire course of the planned drillings/screws, and good assessment of the earlier correction.

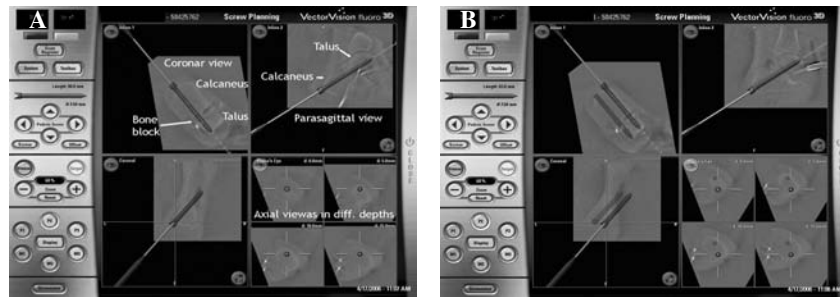


Fig. 2: Planning of the drilling with the Vectorvision fluoro 3D software. A virtual screw with the planned length and diameter of the screw (here 7.5 mm instead of actual 7.3 mm diameter) is placed digitally by the surgeon on the screen of the CAS device.

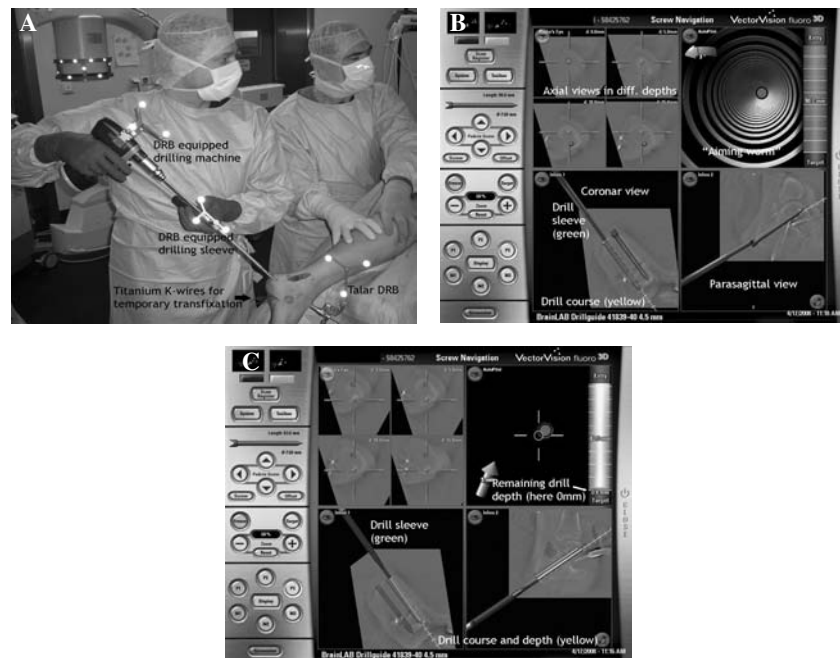


Fig. 3: Retrograde drilling with starting point at the posterior portion of the calcaneal process and visualization on the screen in realtime. **A**, The operative field. **B** and **C**, The screen of the CAS device with an axial reformation, a parasagittal reformation, four axial reformations at different depths, the “aiming worm”, and a display for the planned and achieved depth. The “aiming” worm contains a red point and a virtual worm leading to that point. The surgeon hit the red point which resulted in correct direction and depth of the drilling. One drilling is shown at the beginning (**B**) and the other at the end (**C**) of the planned depth. The equipment of the drilling sleeve with a DRB is important for the correct direction of the drilling.

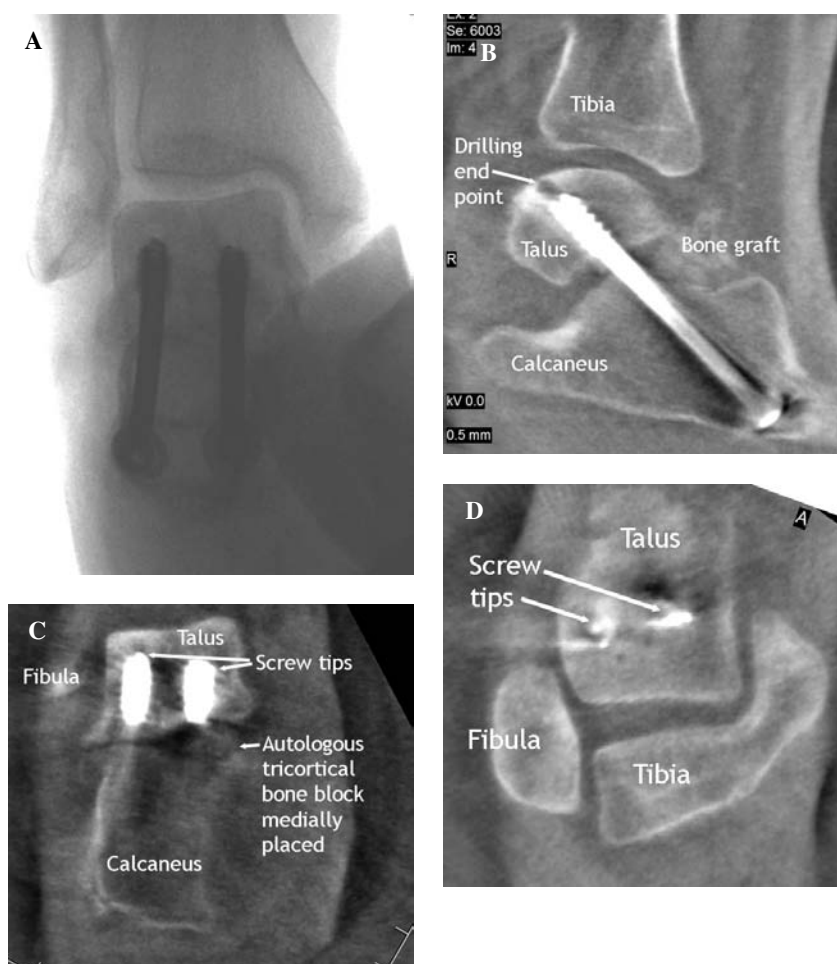


Fig. 4: Accuracy of the drilling and correction with a second 2D- and 3D-ARCADIS scan after insertion of two 7.3-mm screws showing the exact course of the drillings/screws as planned. (A, 2D anteroposterior view; B, parasagittal reformation; C, 3D coronal reformation; D, 3D axial reformation).

DISCUSSION

One of the most important issues in extended hindfoot fusion is to obtain a correct and stable position of the foot. In many instances, there are challenges such as bone loss, deformity, and instability. However, implant position may play a role in obtaining a reliable result. This technical tip does not focus on the problem of bone loss or deformity but on correct implant positioning. Still, the problem of bone loss was addressed by using bone autograft; the problem of deformity was addressed by using CAS guidance for the correction, and the problem of stability was treated by using the two 7.3-mm screws. The correct placement of these and any other screws for fixation in a subtalar correction arthrodesis can be difficult.

We have previously introduced a 2D imaging-based Computer Assisted Surgery (CAS) guided drilling for screw placement.^{5,6} Due to difficulties in planning such as difficult visualization of bones and starting and endpoints for the drilling, and consequent potential inaccuracies like a wrong starting point, length, direction or endpoint of the screws, we

have switched to a 3D imaging-based method for the drilling. This new method of 3D imaging-based CAS guided drilling (ARCADIS) for the screw placement in a subtalar correction arthrodesis is introduced. In the presented case, the screw insertion was accurate. We are not aware of any publication in which the accuracy of screw insertion was compared between 3D imaging guided vs. nonguided insertion. We feel that this method will be the standard for validation of non-navigated techniques in the future.

The cost of the device for navigation and intraoperative 3D-imaging including software amounts to approximately 500,000 Euro (775,000 US Dollars). The annual cost for maintenance is approximately 10,000 Euro (15,500 US Dollars). The device was not purchased for the described technique alone but for all kinds of navigation such as pedicle screw placement, iliosacral screw placement, femoral fracture reduction, knee arthroplasty, high tibial osteotomy, distal tibial osteotomy, and foot and ankle correction arthrodeses. The device has been used for 100 navigations and additionally for 300 intraoperative 3D-imagings (comparable to computer tomography-CT). With a planned depreciation of

the device of 5 years, the annual cost amounts to 110,000 Euro (170,500 US Dollars) or 275 Euro (425 US Dollars) per navigation and/or 3D-imaging case. We feel that the cost per case is acceptable.

REFERENCES

1. **Citak, M; Kendoff, D; Kfuri, M, Jr.; et al.:** Accuracy analysis of Iso-C3D versus fluoroscopy-based navigated retrograde drilling of osteochondral lesions: a pilot study. *J Bone Joint Surg Br.* **89**:323–326, 2007. <http://dx.doi.org/10.1302/0301-620X.89B3.18424>
2. **Easley, ME; Trnka, HJ; Schon, LC; Myerson, MS:** Isolated subtalar arthrodesis. *J Bone Joint Surg Am.* **82**:613–624, 2000.
3. **Marti, RK; de Heus, JA; Roolker, W; Poolman, RW; Besselaar, PP:** Subtalar arthrodesis with correction of deformity after fractures of the os calcis. *J Bone Joint Surg Br.* **81**:611–616, 1999. <http://dx.doi.org/10.1302/0301-620X.81B4.9386>
4. **Rammelt, S; Grass, R; Zawadski, T; Biewener, A; Zwipp, H:** Foot function after subtalar distraction bone-block arthrodesis. A prospective study. *J Bone Joint Surg Br.* **86**:659–668, 2004. <http://dx.doi.org/10.1302/0301-620X.86B5.14205>
5. **Richter, M:** Computer Based Systems in Foot and Ankle Surgery at the Beginning of the 21st Century. *Fuss Sprungg.* **4**:59–71, 2006. <http://dx.doi.org/10.1007/s10302-006-0154-z>
6. **Richter, M; Geerling, J; Frink, M; et al.:** Computer Assisted Surgery Based (CAS) based correction of posttraumatic ankle and hindfoot deformities—Preliminary results. *Foot Ankle Surg.* **113**–119, 2006. <http://dx.doi.org/10.1016/j.fas.2006.02.003>
7. **Richter, M; Geerling, J; Zech, S; Goesling, T; Krettek, C:** Intraoperative three-dimensional imaging with a motorized mobile C-arm (SIREMOBIL ISO-C-3D) in foot and ankle trauma care: a preliminary report. *J Orthop Trauma.* **19**:259–266, 2005. <http://dx.doi.org/10.1097/01.bot.0000151822.10254.db>
8. **Richter, M; Geerling, J; Zech, S; Krettek, C:** ISO-C-3D based Computer Assisted Surgery (CAS) guided retrograde drilling in a osteochondrosis dissecans of the talus: a case report. *Foot.* **15**:107–113, 2005. <http://dx.doi.org/10.1016/j.foot.2005.02.004>
9. **Thermann, H; Hufner, T; Schratt, E; et al.:** Long-term results of subtalar fusions after operative versus nonoperative treatment of os calcis fractures. *Foot Ankle Int.* **20**:408–416, 1999.
10. **Trnka, HJ; Easley, ME; Lam, PW; et al.:** Subtalar distraction bone block arthrodesis. *J Bone Joint Surg Br.* **83**:849–854, 2001. <http://dx.doi.org/10.1302/0301-620X.83B6.10537>
11. **Weber, BG:** Subtalare Arthrodesen nach Kalkaneusfrakturen. *Z Unfallmed Berufskr.* **64**:66, 1971.
12. **Zwipp, H:** *Chirurgie des Fusses*, Wien New York, Springer Berlin Heidelberg New York, 1994.